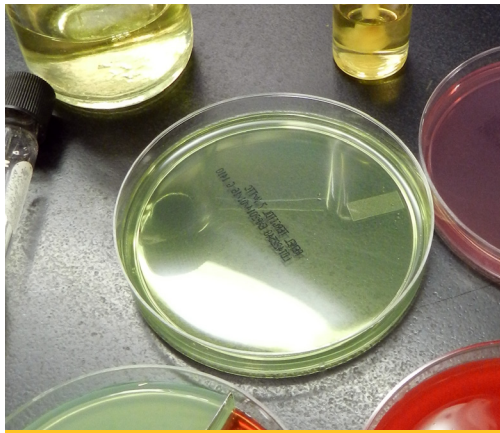



Winter 2020, Vol. 4, No. 1

In This Issue

Director's Corner
Calendar

Bench Notes

- New EIA test submission requirements
- Canine distemper virus in vaccinated animals
- Mycotoxins in feed

Disease Updates

- 2019 equine necropsies report
- 2019 bovine abortions report

Mini Case Report

- Diarrhea!

A newsletter about diagnostic trends at the laboratory, animal health topics, interesting cases and new test offerings.

www.vdl.ndsu.edu

We welcome comments, questions and suggestions. Please email us at vetlab.ndsu@ndsu.edu or call the laboratory at (701) 231-8307.

NDSU Veterinary Diagnostic Laboratory

Director's Corner

The laboratory is busy gearing up for the rush of cases that typically accompany calving season and has been receiving abortion cases during the last month. This edition of the newsletter contains a summary of last year's abortion case data. Although overall abortion cases were down last year, the data give you a perspective of frequency and type of causes observed.

This year, the laboratory is changing the methodology used to detect bovine neonatal diarrhea agents. Instead of electron microscopy and microscope evaluation of acid-fast stained smears, PCR will be used for detection of bovine coronavirus, bovine rotavirus and *Cryptosporidium* spp. The new methods will allow quicker turn-around time and much greater sensitivity. We are not making any changes to scour screening for other species.

Other activities at the lab have been focused on implementing a new laboratory information system, which we hope will be going live this summer. Please be sure to read through the important U.S. Department of Agriculture (USDA) changes that are in place for Coggin's testing.

Thank you for your continued support and interest in the laboratory, and we hope everyone has a wonderful spring.

Sincerely,

Brett T. Webb, D.V.M., Ph.D., DACVP
NDSU-VDL Director

Calendar: Winter-Spring Closures

April 10 — Good Friday

May 25 — Memorial Day

NDSU VETERINARY DIAGNOSTIC
LABORATORY
North Dakota State University

Bench Notes

The Serology Lab will begin daily **equine infectious anemia (EIA)** ELISA testing in March. Please be aware that USDA guidelines released in October 2019 require several changes in how the laboratory processes EIA submissions. The laboratory must ensure all forms are complete and accurate.

Specifically, all fields must be completed or indicate “not applicable.” The regulations also limit the NDSU-VDL’s ability to correct form errors. In addition, only the most current VS 10-11 EIA form can be accepted after April 15, 2020. Before submitting samples, be sure to review the new requirements on our webpage (www.vdl.ndsu.edu/wp-content/uploads/2020/01/EIA-test-changes-1-15-20.pdf).

The molecular lab identified **canine distemper virus** infection in a young, symptomatic, vaccinated dog. Sequence analysis reveals the virus to be genetically related to strains of a unique wild-type canine distemper virus clade that were circulating in North Dakota in 2017-2018 (Annis, E., Newell, T.K., Dyer, N., Wilkes, R.P. Phylogenetic analysis of wild-type strains of canine distemper virus circulating in the United States. *Virol J* 2018;15(1):118).

In one other case submitted to the NDSU-VDL in 2017, a young, vaccinated dog became infected with canine distemper virus and was euthanized after developing neurologic signs. The source of these unique North Dakota strains remains unknown. Therefore, despite vaccination status, canine distemper should remain on the differential list for dogs with vomiting, diarrhea and/or coughing. Isolation and proper disinfection protocols are recommended in all cases of respiratory or enteric disease.

Mycotoxins are detected frequently in feed submitted to the toxicology lab. The 2019 Dakota weather often was challenging: either too wet or too dry, cool to frigid temperatures, and an early autumn snowfall. Some of last year’s corn harvest submitted to the toxicology lab revealed tortuous growth and mold invasion of corn and the cob (Figure 1a).

Typically, the lab detected mycotoxins produced by *Fusarium* spp. (Figure 1b) and some *Penicillium* spp. Black mold growing on corn indicated possible *Alternaria* or *Cladosporium*, with the latter mold not a recognized mycotoxin producer.

Figure 1: (A) Moldy, tortuous corn cobs submitted to the lab from the 2019 harvest; (B) *Fusarium* spp. invasion exhibited by the pink mold on the corn husk (upper right) and white fungal hyphae growing on the corn kernels. (Michelle Mostrom, NDSU)



Mold growth does not always mean toxin production. However, 2019 laboratory analyses often found multiple *Fusarium* mycotoxins: DON (deoxynivalenol or vomitoxin), zearalenone, fumonisins and, occasionally, the more toxic T-2 and H-T2 toxins. Submitted corn has been wet (stored wet or piled in wet/cool conditions), which promotes mold growth and, subsequently, mycotoxin production. If 2019 is like 2009, the corn left in the field eventually can dry and be less likely to have mold/mycotoxin issues.

When molds are present in livestock feeds, the best approach is to discard the moldy portions of the feed and use what appears normal as animal feed. The lab urges livestock producers to be proactive and test feedstuff that appears to be moldy for mycotoxins before feeding to animals, particularly pregnant animals.

Try to collect a representative sample of the feed. The best method is to collect multiple samples of grain while transporting the feed from the field to bins or to a truck, or collect multiple samples of hay (e.g., probe) or silage during feeding.

Ruminants on an adequate ration often have rumen microflora that metabolize some of these mycotoxins to less toxic compounds. Different mold toxins can cause a variety of clinical signs in different species.

Initial clinical signs of toxic feed can be feed refusal, poor weight gain and possible diarrhea. With continual mycotoxin exposure or high-dose exposure to toxins, damage can occur to the animal’s liver, kidneys, brain, fetus and other organs.

The NDSU-VDL can test for the more common mycotoxins in feed that are known to cause harm in animals and provide some guidance for feeding contaminated feeds. We recommend using a testing laboratory that is not also in the business of selling “mycotoxin binders,” which could be a conflict of interest.

The U.S. Food and Drug Administration (FDA) has regulatory limits or advisory guidelines on contamination of several mycotoxins in human and animal feeds. These mycotoxin limits in food/feed can vary significantly with susceptible species, age of animal and production status. The mycotoxin guidelines are available on the FDA website or the National Grain and Feed Association website (www.ngfa.org), or by contacting the NDSU-VDL Toxicology section.

Disease Updates

Twenty-six horse autopsies were performed at the NDSU-VDL in 2019, a number that has been climbing steadily during the last five years. Infectious causes were noted in only a few cases and included neuropathic equine herpes virus-1 in a foal, bacterial pneumonia in a young mare, presumed colitis X in an older mare, undetermined viral meningoencephalomyelitis in a middle-aged mare and one case of verminous arteritis in an aged gelding. Malignant pheochromocytoma leading to a

renal arterial dissection was noted in one gelding; otherwise, neoplasia was diagnosed rarely. Common findings in older horses included laminitis, arthritis and colic associated with strangulating lipomas, obstructions and entrapments. These made up the bulk of the cases submitted.

With the 2020 **abortion season** upon us, submission of a complete set of fresh and formalin-fixed tissues is paramount to a definitive diagnosis. The most important tissue for evaluation is the placenta. Submissions that include the placenta typically are twice as likely to result in a definitive diagnosis as submissions with no placenta.

During 2019, the NDSU-VDL received **112 bovine abortion** cases, which included whole fetuses submitted for necropsy and general investigation, and tissue samples submitted for general investigation only (Figure 2a). Diagnostic rates showed significantly ($P=0.024$) more cases with an unknown etiology in field-performed, compared with lab-performed necropsies.

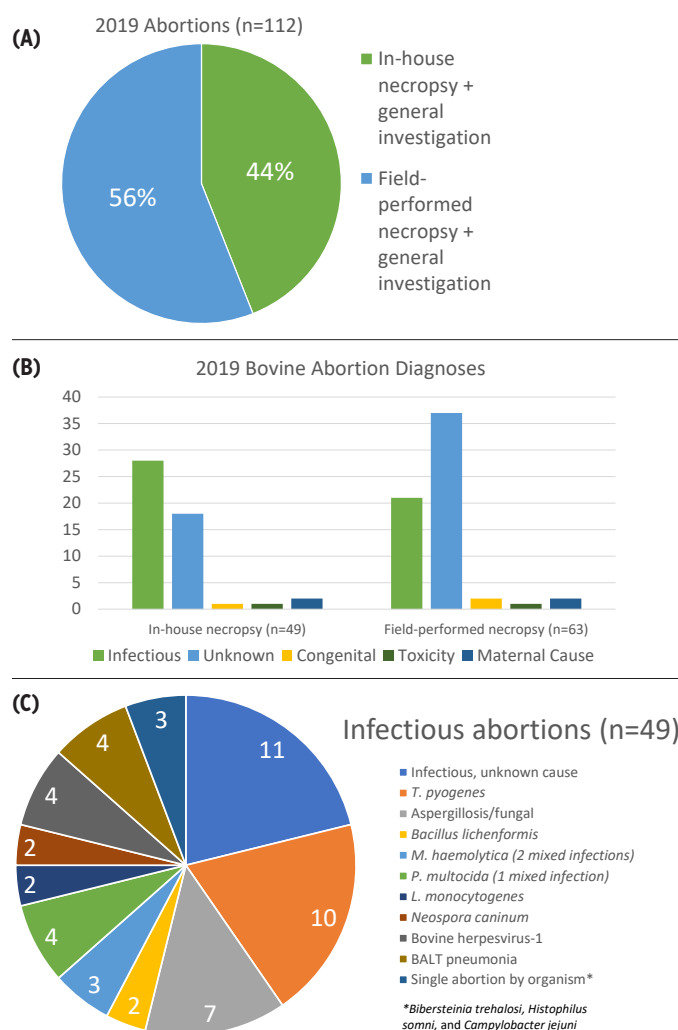


Figure 2: (A) 112 whole-fetus and tissue abortion cases were submitted in 2019. (B) In-house necropsy cases were more likely to yield an etiologic diagnosis, compared with field-performed necropsies. (C) Infectious abortive agents included bacteria, viruses, fungi and protozoa.

Specifically, the lab performed 18/49 cases (37%) versus 37/63 tissue submission cases (59%) with unknown etiologic diagnoses. The primary reason for the difference in diagnostic rates is the availability of a complete set of tissues for histopathology and ancillary testing when full necropsies were performed by the laboratory.

Abortion trends for 2019 are categorized by cause in Figure 2b. Notably, abortions with infectious etiologies had higher rates of agent identification/recovery (viral, fungal, bacterial, protozoan) for in-house necropsy and general investigation, compared with field-performed necropsy and general investigation only. Causes of infectious abortions are shown in Figure 2c.

Specimens to include for optimal results:

- Fresh and formalin-fixed placenta
- Whole fetus/neonate (recommended) or fresh and fixed tissues, including:
 - Fresh brain, heart, lung, liver, kidney, spleen, abomasal fluid, thymus, thyroid, lymph node, fetal eyeball/vitreous humor (for nitrate analysis) and any tissue with a suspected lesion
 - Brain, thymus, heart, lung, liver, kidney, spleen, conjunctiva, adrenal gland, skeletal muscle and any tissue with a suspected lesion
 - Feed and water
 - Maternal sera (acute and convalescent)

Mini Case Report

As of this writing (early February), a few scours cases already have been submitted to the NDSU-VDL, which inspired this issue's mini case report: diarrhea! Scours is a major problem in neonatal and young calves, leading to sudden death and widespread outbreaks.

Depending on age and other clinical signs, the main pathogenic agents typically identified include viruses (coronavirus and rotavirus in young neonates), bacteria (*Escherichia coli* in neonates and salmonellosis in post-neonatal calves) and protozoa (coccidiosis in older neonates up to yearlings and beyond). However, diarrhea is not only a calf problem.

Throughout the autumn and winter, numerous whole-animal, tissue and fecal samples were submitted from adult cattle with a history of chronic weight loss and variable loose stool and diarrhea. Thickened, corrugated and red small intestinal mucosa (Figure 3a), especially in the ileum, is highly suspicious for mycobacteriosis (*Mycobacterium avium* subspecies *paratuberculosis*) or Johne's disease.

Microscopically, the intestinal mucosa is expanded by histiocytes that are swollen with bacteria (Figure 3b). Acid-fast stain for the micro-organisms is the gold standard for diagnosis (Figure 3c). However, PCR is a very sensitive antemortem method performed at the NDSU-VDL to identify disease and even quantifies shedding in infected animals. In addition, serologic assays can determine exposure to the bacterium and are an inexpensive way to screen a herd for the disease.

NDSU Veterinary Diagnostic Laboratory

P.O. Box 6050
NDSU Department 7691
Fargo, ND 58108-6050

NON-PROFIT
U.S. POSTAGE
PAID
FARGO, ND
PERMIT NO. 818

With the hope of spring and, thus, puppy and kitten season on the horizon, canine and feline parvovirus (panleukopenia) cases are expected to increase into the summer months. Unlike Johne's disease, infected animals typically have thin intestinal mucosa and segments of the small intestine may be red (Figure 4a). Under the microscope, the mucosa is tattered with surface damage, while crypts are often dilated and filled with necrotic debris and inflammatory cells (Figure 4b). Regional mesenteric lymph nodes frequently are enlarged, but lymphoid depletion occurs within previously expanded follicles (Figure 4c), which is reflective of the virus's tropism for lymphoid tissues.

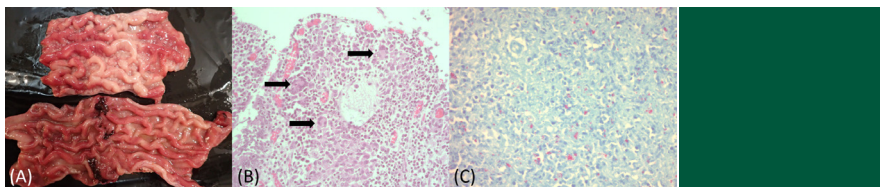


Figure 3: (A) Thickened, corrugated and red mucosa line the small intestine of a cow with Johne's disease. (B) Microscopically, the mucosa is expanded by bacteria-laden histiocytes (arrows) that (C) are acid-fast stain positive (bright pink cells). (Heidi Pecoraro, NDSU)

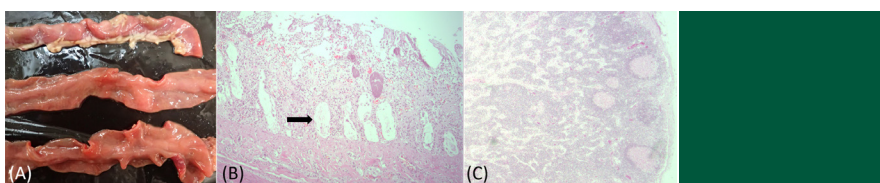


Figure 4: (A) Thin, red mucosa may line the small intestine of a cat with panleukopenia virus. (B) Microscopically, luminal surface mucosa is damaged and deeper crypts are dilated (arrow). (C) Regional mesenteric lymph nodes also may exhibit lymphoid depletion (pink follicles within cortex). (Heidi Pecoraro, NDSU)



Follow us on our social media feeds.

[www.facebook.com/
NDSUVeterinaryDiagnosticLaboratory](https://www.facebook.com/NDSUVeterinaryDiagnosticLaboratory)
[linkedin.com/company/ndsu-veterinary-
diagnostic-laboratory](https://www.linkedin.com/company/ndsu-veterinary-diagnostic-laboratory)

Contact Information

NDSU Veterinary Diagnostic
Laboratory
P.O. Box 6050
NDSU Department 7691
Fargo, ND 58108-6050
Phone: (701) 231-8307

For more information on this and other topics, see www.vdl.ndsu.edu

North Dakota State University and U.S. Department of Agriculture cooperating. NDSU does not discriminate in its programs and activities on the basis of age, color, gender expression/identity, genetic information, marital status, national origin, participation in lawful off-campus activity, physical or mental disability, pregnancy, public assistance status, race, religion, sex, sexual orientation, spousal relationship to current employee, or veteran status, as applicable. Direct inquiries to Vice Provost for Title IX/ADA Coordinator, Old Main 201, NDSU Main Campus, 701-231-7708, ndsu.eoaa@ndsu.edu. This publication will be made available in alternative formats for people with disabilities upon request, 701-231-7881.